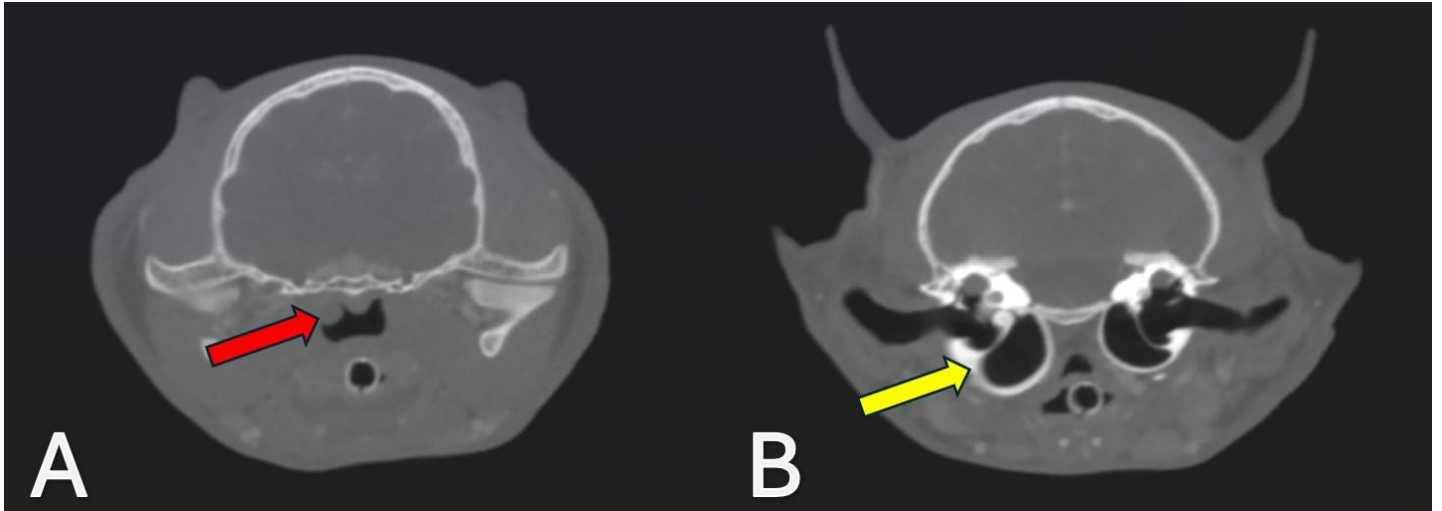
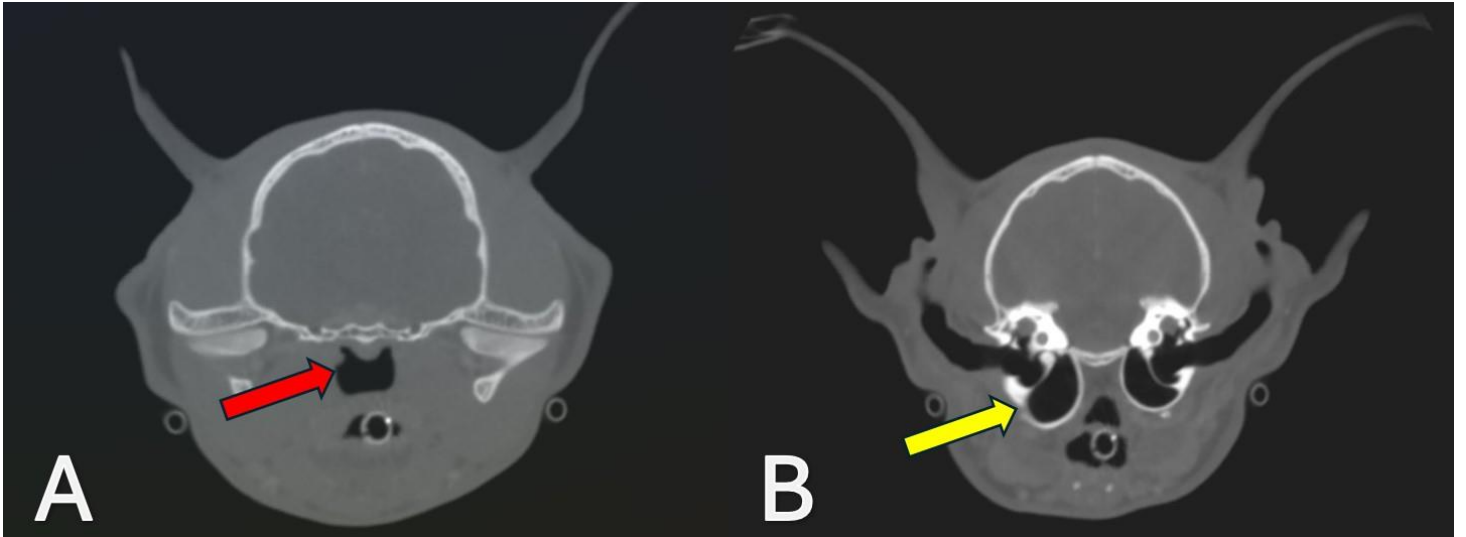


Figure S1.



Supplemental Figure 1 (on-line version only). Second follow-up CT scan (Day 40). The nasopharyngeal mass is smaller (Supplementary Figure 1A). The right tympanic bulla is nearly normal, despite some wall thickening (Supplementary Figure 1B).

Figure S2.



Supplemental Figure 2 (on-line version only). Third follow-up CT scan (Day 82). The nasopharyngeal mass has nearly “resolved” (Supplementary Figure 2A). The tympanic bulla thickening is approaching normal (Supplementary Figure 2B).